

Successful Treatment of Bilateral Refractory Chylous Effusion of Non-Hodgkin Lymphoma Patient with Octreotide

Jennifer I-Hsuan Shen, MS
Ajithkumar Puthillath, MD
Lynn Steinbrenner, MD
Michele Cook, MD
Deborah Farolino, MD, FACP

Abstract

Chylothorax is leakage of the thoracic duct content into the pleural cavity due to congenital defects, trauma, tumor infiltration, postoperative cardiac or esophageal procedures. Traditional approaches to chylothorax include thoracentesis and pleurodesis, which are invasive and often result in significant patient morbidity and mortality. In a patient who is a nonsurgical candidate, octreotide presents a better alternative. Octreotide, an analogue of somatostatin, was first used more than a decade ago to treat chylous effusions. Octreotide's treatment for lymphoma-induced chylothorax has rarely been reported. Through our literature search, we found that our case is among the few bilateral lymphoma-induced chylous effusion cases treated by octreotide in the world. Our patient was treated with octreotide and combined with medium chain triglyceride (MCT) with strict low fat/low calorie diet. After ten days of treatment, there was a significant reduction of chylous effusion. Patient was subsequently discharged and recovered significantly without recurrence for the past eight months.

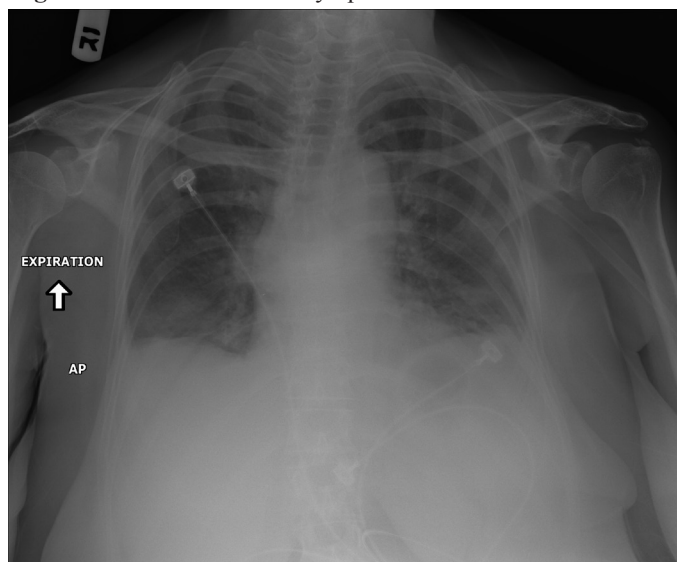
Keywords: Lymphoma, chylothorax, octreotide, thoracentesis, Medium Chain Triglycerides (MCT).

Case

The patient is a 64 year-old female with Stage II Non-Hodgkin Lymphoma involving mediastinum, thoracic T5 to T12, and adjacent GI wall. The patient was initially treated with 3000 cGy

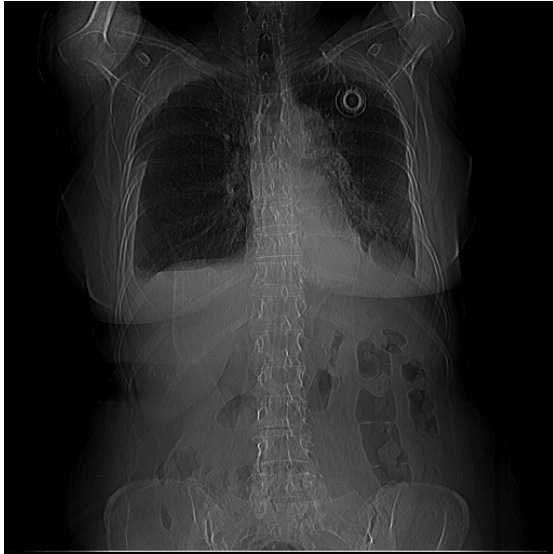radiation to thoracic spine followed by R-CHOP. Ten days after her first course of R-CHOP, she presented to the emergency room with severe dyspnea, pleuritic chest pain, and dry cough. Chest x-rays (Figure 1) showed extensive bilateral pleural effusion. Initial left thoracentesis revealed the presence of a chylous effusion, and subsequent analysis of the right effusion revealed the same. The triglyceride levels were 3397 mg/dl and 2218 mg/dl on the left and right side of the chest respectively.

Figure 1: Patient's chest x-ray upon admission



Following three days of continuous infusion octreotide at 24-50 mcg/hour and a low-fat diet supplemented with medium chain triglycerides (MCTs), patient had recurrence of bilateral chylothorax. The second set of bilateral thoracentesis showed triglyceride levels were 438 mg/dl and 441 mg/dl on the left and right side of her chest respectively. However, it represents an 80% and 87% decrease on the left and right sides of her chest accordingly since first set of bilateral thoracentesis. Re-accumulation of the chyle stopped after second set of bilateral thoracentesis, and she required no further pleural interventions. Chest X rays at two months showed complete resolution (Figure 2).

Figure 2: Chest x-ray two months after discharge



During her octreotide treatment, the patient experienced low-grade fever, minor hyperglycemia, and diarrhea for the first few days of octreotide initiation, which resolved after two days when octreotide was stopped accompanied by lab tests to investigate the origin of fever. No infectious etiology was delineated. Mild temperature elevated again after patient was started back on octreotide, and the temperature resided after a few days of treatment.

Dietary modification for our patient initially consisted of Enlive® and a clear liquid diet. She was transitioned to a low-fat (40 to 70 mg of fat per day) diet and medium chain triglycerides (MCTs) on day six, and she reported an improved mood and appetite. Total parenteral nutrition was not considered due to possible complications and patient's immune-suppressive state. On day 14 of inpatient stay, patient was discharged home on subcutaneous octreotide injection (.05 mg/ml). After one month of outpatient treatment, the MCT diet and octreotide were successfully discontinued, and there has been no recurrence of chylothorax since then.

Discussion

Chyle is a white milky fluid that is rich in triglyceride, calories, vitamins, and immunoglobins.^{1,2} Chyle is produced at a rate of from two to four liters per day and can increase to five liters per

day on a high-fat diet. Chyle drains into the venous system via the thoracic duct at the junction of the internal jugular and subclavian veins. Chylous fluid consists of greater than 30 gm/L of protein, 4-40 g/L of lipid (mostly triglycerides), and cells (primarily lymphocytes).²

Chylothorax is leakage of the thoracic duct contents into the pleural cavity due to congenital defects, trauma, tumor infiltration, and postoperative cardiac or esophageal procedures. Traditional approaches to chylothorax include thoracentesis and pleurodesis, which are invasive and often result in significant patient morbidity and mortality. Repetitive or continuous drainage of chylothoraces can cause loss of lymphocytes, immunoglobulins, and fats, which can further compromise the patient's immune status and lead to cachexia over a short period of time.

Approximately 60% of the cases are due to lymphoma. The diagnostic criteria vary, but the fluid is often milky appearing and the triglyceride content of the pleural fluid should be greater than 150.¹

The mainstay in the management of chylothorax is to decrease the rate of flow of chyle. This can be done with surgery or medical management. Surgical intervention is indicated when chylous effusion accumulates at a rate that is more than 1500 ml per day for five to seven days.³ Ligation at the site of lymphatic leakage is an option, but can involve an extensive thoracotomy and requires surgical expertise, and was not a good option for our patient due to her immunocompromised state and extensive mediastinal involvement. Other surgical techniques include pleurocentesis, pleuroperitoneal or pleurovenous shunt,⁴ thoracoscopy suture, or thoracoscopy with fibrin glue application.⁵ Less invasive method using pleurodesis with talc administration still requires usage of chest tube or a thoracoscope. There were articles reporting 58% of chylothorax patients resolving symptoms with radiation treatment;⁶ however, our patient's chylothorax appeared after a course of radiation. All these methods, although used often in chylothorax cases, can cause significant morbidity and even mortality.

Dietary management is the key and should include restriction of long chain fatty acids and triglycerides, which are absorbed into the lymphatic system. Medium chain triglycerides (MCTs) are often recommended, because they are absorbed directly across the GI mucosa into the portal circulation.⁷ Often parenteral nutrition is required, but should be reserved when there are no other options. With reduction in chyle flow, there is a reasonable chance that a spontaneous closure of the leak may occur, thus avoiding the morbidity and mortality associated with tube thoracotomy.^{8,9}

Octreotide, an analogue of somatostatin, was first used more than a decade ago to treat chylous effusions. It can be administered intravenously, subcutaneously, or intramuscularly for both pediatric and adult chylothorax cases.^{8,9} In a patient who is a nonsurgical candidate, octreotide presents a useful adjunct.^{1,10,11,12,13} However, even though octreotide has been used clinically for over a decade, its usage for lymphoma-induced chylothorax has rarely been reported.

Through our literature search, we found that our case is among the few bilateral lymphoma- induced chylous effusion cases treated by octreotide in the world.¹⁴ Our patient was treated with octreotide and combined with medium chain triglyceride (6 to 12 carbon chain triglycerides) with strict low fat/low calorie diet. After six days of treatment, there was a significant reduction of chylous effusion. Adverse effects were limited to minor hyperglycemia and flu-like symptoms when first initiated, but resolved within a week. After one month follow up, octreotide treatment stopped. The patient recovered significantly and resumed activities of daily living and has not had recurrence of chylothorax for eleven months since discharge.

Jennifer I-Hsuan Shen, MS, is a medical student at the State University of New York at Buffalo, Medicine and Biomedical Sciences.

Ajithkumar Puthillath, MD, is an oncologist at Stockton Hematology and Oncology.

Lynn Steinbrenner, MD, is Associate Professor of Medicine, Department of Medicine, State University of New York at Buffalo, Medicine and Biomedical Sciences.

Michele Cook, MD, is Clinical Assistant and Professor at State University of New York at Buffalo, Medicine and Biomedical Sciences, and Staff Radiologist at WNY VA.

Deborah Farolino, MD, FACP, is Hematology Oncology Attending and Assistant Professor of Medicine, Buffalo VA Medical.

Potential Financial Conflicts of Interest: By AJCM® policy, all authors are required to disclose any and all commercial, financial, and other relationships in any way related to the subject of this article that might create any potential conflict of interest. The authors have stated that no such relationships exist.

References

1. Evans J, Clark MF, Mincher L, et al. Chylous effusions complicating lymphoma: A serious event with octreotide as a treatment option. *Hematol Oncol.* 2003;21(2):77-81.
2. Steward W, Hunter WA, O'Byrne, Snowden J. Chemotherapy and Haematopoietic Stem Cell Transplantation. In: *Intestinal failure. Nightingale J* (ed). Greenwich Medical Media Limited, London. 2001:73.
3. Agrawal V, Sahn SA. Lipid pleural effusions. *American Journal of the Medical Sciences.* 2008;335(1):16-20.
4. Tanaka E, Matsumoto K, Shindo T, et al. Implantation of a pleurovenous shunt for massive chylothorax in a patient with yellow nail syndrome. *Thorax.* 2005;60(3):254.
5. Zoetmulder F. Thoroscopic ligation of a thoracic duct leakage. *Chest.* 1994;106(4):1233-4.
6. Roy P, Carr D, Payne WS. *The problem of chylothorax.* 1967;42:457.
7. Nakabayashi H, Sagara H, Usukura N, et al. Effect of somatostatin on the flow rate and triglyceride levels of thoracic duct lymph in normal and vagotomized dogs. *Diabetes.* 1981;30(5):440-5.
8. Markham KM, Glover J, Welsh RJ, Lucas RJ, Bendick PJ. Octreotide in the treatment of thoracic duct injuries. *Am Surg.* 2006;66(12):1165-1167.
9. McCray S, Parrish CR. When Chyle leaks: Nutrition management options. *Practical Gastro.* May 2004:60-76.
10. Blaz Lesina B, Maria Aburto B. Octreotide for bilateral chylothorax secondary to lymphoma. Report of one case. *Rev Med Chile.* 2005;133(12):1473-6.
11. Demos NJ, Kozel J, Scerbo JE. Somatostatin in the treatment of chylothorax. *Chest.* 2001;119(3):964-6.
12. Kalomenidis I. Octreotide and chylothorax. *Curr Opin Pulm Med.* 2006;12(4):264-7.
13. Gomez-Caro AA, Moradiellos Diez FJ, Marron CF, et al. Conservative Management of Postsurgical Chylothorax with Octreotide. *Asian Cardiovascular and Thoracic Annals.* 2005;13(3):222-4.
14. Blaz Lesina B, Maria Aburto B. Octreotide for bilateral chylothorax secondary to lymphoma. Report of one case. *Rev Med Chile.* 2005;133(12):1473-6.