



CASE REPORT

A Rare Case of Pneumocystis Pneumonia

Swati Sharma, MD
Reginald Wills, MD

Abstract

Pneumocystis jirovecii pneumonia (commonly called Pneumocystis pneumonia or PCP) is an opportunistic infection that occurs in immunocompromised individuals. Although Human Immunodeficiency Virus (HIV) infected patients with a low CD4 (cluster of differentiation 4) count are at highest risk of PCP, it is a significant cause of pneumonia in other immunodeficient patients. Non-HIV patients at risk are those with cancer, particularly hematologic malignancies, patients receiving glucocorticoids, chemotherapeutic agents and other immunosuppressive medications, hematopoietic stem cell and solid organ transplant recipients, patients with primary immunodeficiencies, and severe malnutrition. Only a few cases have been reported in patients without any known immunodeficiency. We report the unusual case of pneumocystis pneumonia in a previously healthy non-HIV patient who was not on any immunosuppressant.

Case Report

A 32-year-old female with no significant past medical history, who immigrated from Ethiopia four years prior to presentation, came to the emergency department with fever, dry cough, and generalized abdominal pain for three weeks. Patient was admitted with provisional diagnosis of dehydration and gastroenteritis. Patient also reported nausea and vomiting for three weeks. She had non-bloody diarrhea which lasted for four days and had resolved. She denied any sick contacts or recent travel.

On further review of systems, she denied any dysuria or abnormal vaginal discharge. Her last menstrual period was six days before admission. She reported appetite loss, fatigue, generalized body ache, and ten-pound weight loss in previous three weeks. She had no known allergies. She was taking over-

the-counter ibuprofen for pain and denied smoking, alcohol, or use of illicit drugs. She was single, educated till twelfth grade, and unemployed.

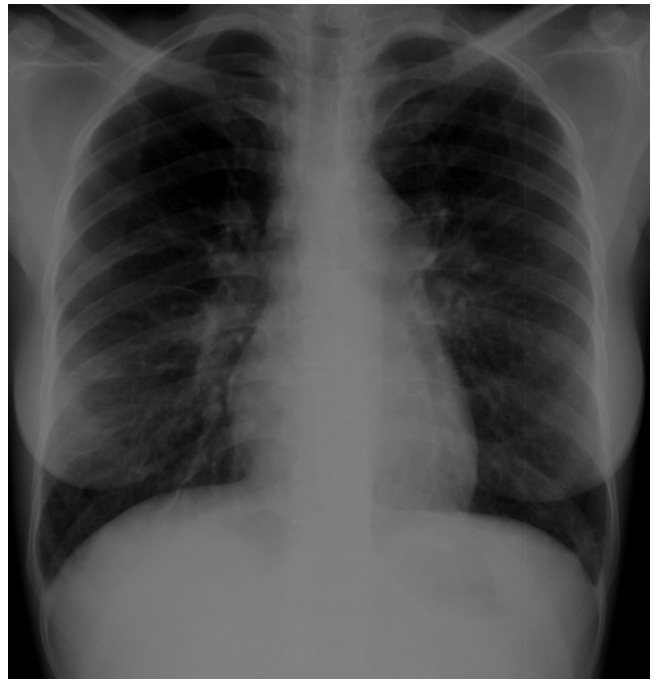


Figure 1. Chest x-ray showing prominent septal lines and interstitial disease.

On physical examination, her temperature was 100.6 Fahrenheit (F), pulse was 133/min, blood pressure was 93/60 mm Hg, and respiratory rate was 20/min. She was saturating 99% at room air, and her body mass index was 14.9. On exam, cachexia and generalized abdominal tenderness were noted. No other abnormalities were identified on multi-systemic exam.

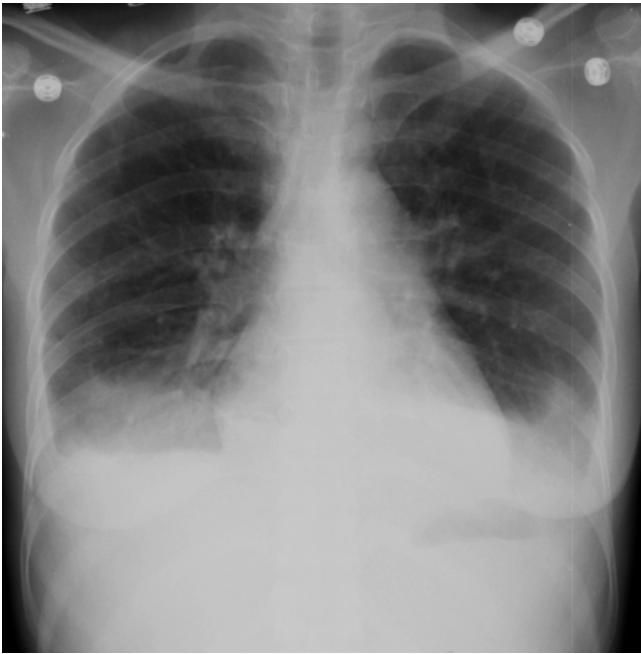

Figure 2. Bilateral pleural effusions and lower lobe infiltrates seen on chest x-ray.

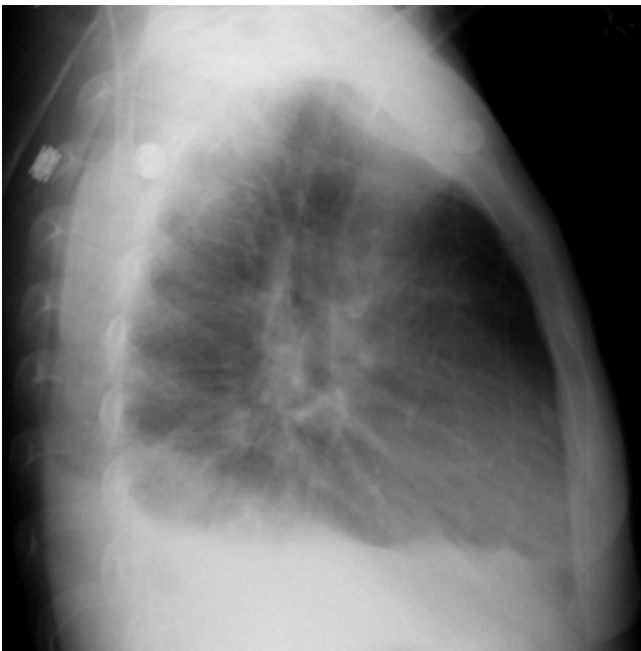

Figure 3. Bilateral pleural effusions and lower lobe infiltrates seen on chest x-ray.

Laboratory work-up showed leukocytes of 4400/cm but a bandemia of 28% and an elevated sedimentation rate of 65 mm/hr. Initial chest x-ray showed prominent bilateral septal lines, which was reported as interstitial disease vs. viral pneumonia (Figure 1). Tuberculin skin test was positive (21 mm), but three acid-fast bacilli smears (AFB) were negative. Pan-cultures and influenza, HIV antibody and viral load, hepatitis, malaria, parvovirus, Epstein-Barr virus, and histoplasma tests were all negative. Syphilis, neisseria gonorrhoeae, and chlamydia tests were negative.

In the first hospital week, patient had persistent fever with a maximum temperature of 103.4 F. Repeat chest x-ray showed bilateral infiltrates and effusions (Figure 2 & 3). Computed tomography of chest showed bilateral lower lobe infiltrates, bilateral mild pleural effusions, and few mediastinal and hilar lymph nodes. She was started on vancomycin, piperacillin-tazobactam, caspofungin, and metronidazole after an infectious disease consultation. Bone marrow biopsy demonstrated mild hypercellular marrow and trilineage hematopoiesis but no evidence of granuloma or malignancy. On consultation with the pulmonary team, bronchoscopy was recommended, but patient refused initially.

In the second hospital week, patient continued to have fever on broad spectrum antibiotics. She consented for bronchoscopy finally but developed shortness of breath the following day. Her saturation at room air was found to be 64% and chest x-ray showed worsening of bilateral infiltrates and effusions, with right side more severely involved than left (Figure 4). Therapeutic thoracentesis was done. 850 ml fluid was drained from right side and 550 ml from left side. Pleural fluid was transudative, and cultures were negative. AFB and silver stains were negative, and there were no malignant cells.

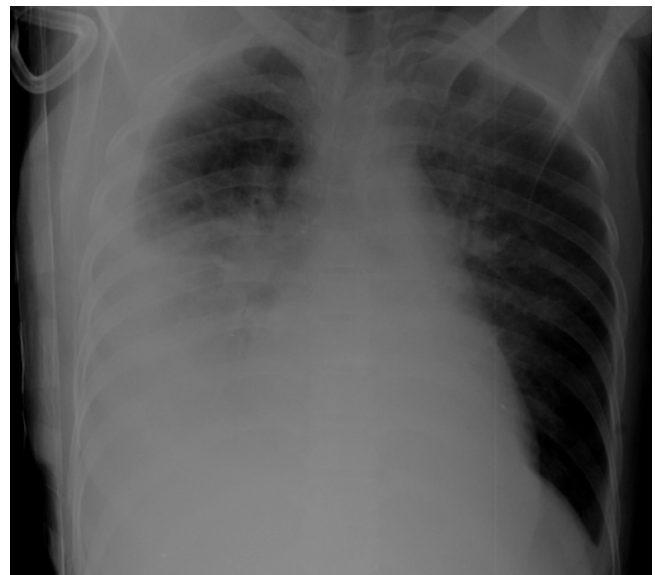

Figure 4. Lateral decubitus chest x-ray demonstrates layering of effusion on right and bilateral consolidation.

After thoracentesis, her hypoxia resolved and bronchoscopy was done. Bronchial washings were positive for *Pneumocystis Jirovecii*. Testing for malignancy and AFB was negative. Treatment for PCP was started with Trimethoprim-sulphamethoxazole (TMP-SMX) and prednisone. Autoimmune and rheumatologic work-up was done. Anti-nuclear antibody was positive with a nucleolar pattern of 1:80. Anti-phospholipid and scleroderma antibodies were also positive. Rheumatoid factor and serum angiotensin-converting enzyme level were both normal. Anti-deoxyribonucleic acid, anti-smith, and anti-sjogren's antibodies were negative. Rheumatology consult service considered overlap syndrome as one of the possibilities. Patient

showed clinical and radiological (Figure 5) improvement and was discharged with instructions to complete twenty-one days treatment with TMP-SMX. She was counseled to follow-up in our out-patient clinic and with rheumatology clinic. Since then, she has been seen at our clinic twice and is in a fair state of health. She has not followed with the rheumatology clinic.

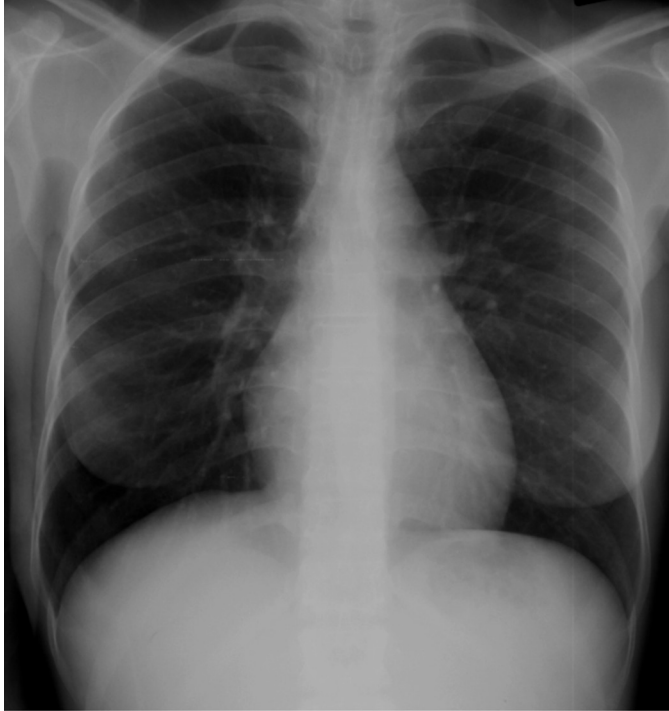


Figure 5. Normal chest x-ray.

Discussion

PCP is a potentially life-threatening infection that occurs in primarily HIV patients with CD4 below 200, but also in non-HIV patients with immunosuppression. The common underlying factor is presence of cellular immunodeficiency. Approximately one to two percent of patients with rheumatologic diseases develop PCP, usually in the setting of immunosuppressive therapy, particularly combined therapy. In the case discussed, the patient was HIV negative with CD4 of 384. She had a rheumatologic disorder but was not on any immunosuppressant. The relationship between autoimmune rheumatic disorders and opportunistic infections is a potential area of research. One hypothesis is that chronic infections, such as mycoplasma infections, may be present in a variety of autoimmune diseases, and these chronic infections can compromise the immune system, permitting opportunistic infections by other bacteria, viruses, fungi, and yeast.¹ There have been reports of PCP in people who had no known predisposing conditions. Therefore, this pneumonia can manifest in patients with normal CD4 count, and in these cases, PCP is probably associated with qualitative alterations of the cellular immune system.²

Diagnosis of pneumocystis can be difficult, because it cannot be cultured. It is classified as a fungus on the basis of its genomic

characteristics. Though still widely referred to as pneumocystis carinii, the extracellular parasitic organism responsible for infection in humans was renamed pneumocystis jirovecii in 1999. The name is after the Czech parasitologist, Otto Jiroveci, thought to be the first to describe the organism in humans.³ The designation, pneumocystis carinii, is now reserved for the species infecting only rats.

Pneumocystis infection is usually, but not exclusively, confined to the lungs. Fever, non-productive cough, and exertional dyspnea are the typical features.⁴ Physical findings are usually non-specific. Chest x-ray typically shows bilateral interstitial pattern. It can be normal in at least one-third of the cases. Elevated LDH has high sensitivity, and the degree of elevation may provide evidence of severity of illness. Sputum induction is the current standard screening tool for pneumocystis. Polymerase chain reaction assays for induced sputum can increase the diagnostic yield over conventional staining.⁵ If induced sputum is negative and index of suspicion is high, bronchoscopy with broncho-alveolar lavage (BAL) is the diagnostic method of choice.⁶ BAL has more than 95% sensitivity and an even higher specificity. TMP-SMX orally or intravenously is the drug of choice for treatment for PCP in both HIV and non-HIV patients. Patients with severe PCP who have a contraindication to TMP-SMX should receive intravenous pentamidine. Patients should receive 21 days of therapy. Systemic corticosteroids should be administered within the first 72 hours of starting treatment; if partial pressure of oxygen in arterial blood (PaO₂) is less than 70 mm Hg or alveolar-arterial oxygen gradient is more than 35 mm Hg. The rationale is that dying organisms trigger an inflammatory response which can deteriorate oxygenation and hence steroids can play an important role in recovery. TMP-SMX is also the first line agent for prophylaxis. The other drugs that can be used for prophylaxis are dapsone, atovaquone and aerosolized pentamidine.

Most studies on PCP have looked only at HIV patients, so information on non-HIV patients is limited. The organism burden and diagnostic yield of modalities, such as induced sputum and BAL, is higher in HIV patients as compared to those without HIV. The course of PCP in non-HIV patients is fulminant and has higher mortality.⁷ In HIV patients, the course is more indolent, and the prognosis is improving due to early prophylaxis.

In our patient, the index of suspicion for PCP was very low, as there was no obvious cause for immunosuppression. Bronchoscopy should be pursued if infection fails to resolve in a patient without impaired host defenses or if unusual pathogens are suspected.⁸ Bronchoscopy was the key to the diagnosis in our case.

Swati Sharma, MD, is Family Medicine Resident, Howard University Hospital, Washington, DC.

Reginald Wills, MD, is Associate Professor, Department of Community & Family Medicine, College of Medicine, Howard University, Washington, DC.

Potential Financial Conflicts of Interest: By AJCM® policy, all authors are required to disclose any and all commercial, financial, and other relationships in any way related to the subject of this article that might

create any potential conflict of interest. The authors have stated that no such relationships exist.

Conclusion

This is a rare case of PCP in a non-HIV patient not on any immunosuppressive therapy. This case points out that PCP can occur in patients who apparently show no immunosuppression. It brings forward the possibility of a relationship between rheumatic diseases and opportunistic infections. It also illustrates the role of bronchoscopy with BAL as an important diagnostic tool for non-resolving pneumonia and, in particular, for PCP.

References

1. Nicolson GL et al. Rheumatoid Arthritis, Multiple Sclerosis, Lupus, Inflammatory Bowel Diseases, Scleroderma and other Autoimmune and Degenerative Diseases. Autoimmune Illnesses and Degenerative Diseases. *Medical Sentinel*. 1999;4:172-176.
2. Cano S, Capote F, Pereira A, Calderon E, Castillo J. Pneumocystis carinii pneumonia in patients without predisposing illnesses. Acute episode and follow-up of five cases. *Chest*. 1993;104:376-381.
3. Bennett NJ, Gilroy SA. <http://emedicine.medscape.com/article/225976-overview>. Updated March 29, 2011.
4. Wilkin A, Feinberg J. Pneumocystis carinii Pneumonia: A Clinical Review. *American Family Physician*. October 15, 1999.
5. Thomas CF, Limper AH. <http://www.uptodate.com/contents/epidemiology-clinical-manifestations-and-diagnosis-of-pneumocystis-pneumonia-in-non-hiv-infected-patients>. Updated January 4, 2011.
6. Kovacs JA, et al. New insights into transmission, diagnosis, and drug treatment of Pneumocystis carinii pneumonia. *JAMA*. 2001;286:2450-60.
7. Russian DA, Levine SJ. Pneumocystis carinii pneumonia in patients without HIV infection. *Am J Med Sci*. 2001; 321(1):56-65.
8. Niederman MS. Bronchoscopy in Nonresolving Nosocomial Pneumonia. *Chest*. 2000;117; 212S-218S.