

# Soft Tissue and Skin Infections in IVDA: Treatment, Complications, and Use of Imaging

Nancy Lutwak, MD

## Abstract

The patient is a 56-year old male presenting to the emergency department complaining of redness, swelling, and pain of his right forearm. One week prior to arrival, he was injecting cocaine when the needle tip broke off under his skin. He developed cellulitis secondary to a methicillin-resistant *Staphylococcus aureus* (MRSA) infection.

The patient was hospitalized, treated with intravenous vancomycin, and the needle was surgically extracted using ultrasound guidance. The patient did well. Treatment was successful because of appropriate antibiotics, extraction of the foreign body, and adequate tissue penetration of the vancomycin. He was discharged on hospital day nine.

IV drug abusers commonly develop skin and soft tissue infections. Cellulitis may progress to more serious illness if left untreated. Pyogenic myositis, necrotizing fasciitis, osteomyelitis, septic arthritis, abscesses, and bacterial endocarditis could develop. Patients sometimes present subacutely with retained needles.

Use of imaging techniques to detect and treat complications is imperative. Ultrasound-guided removal of foreign bodies is effective. MRI and CT scans are invaluable for detecting deep complications progressing from cellulitis. MRSA infections require aggressive treatment with appropriate antimicrobials for improvement, particularly in patients with human immunodeficiency virus (HIV). Other infective agents should be considered when osteomyelitis is one of the complications.

## Case Presentation

The patient was a 56-year-old male, HIV positive, who chronically used cocaine. He presented to the emergency department

one week after a needle tip broke off in his right forearm while injecting cocaine. He complained of worsening redness, swelling, and pain at the site.

Past medical history was significant for hepatitis C, myocardial infarction, chronic obstructive pulmonary disease, cardiomyopathy, and depression.

The patient lived in a shelter, smoked one pack of cigarettes per day, and drank one beer daily. He used cocaine and marijuana.

Medications included aripiprazole, bupropion hydrochloride, carvedilol, ipratropium inhaler, lisinopril, simvastatin, and trazodone hydrochloride. However, he was not taking the medications prescribed.

Physical examination revealed pulse of 61, temperature of 97.8°F, respiratory rate of 16, and blood pressure of 121/80.

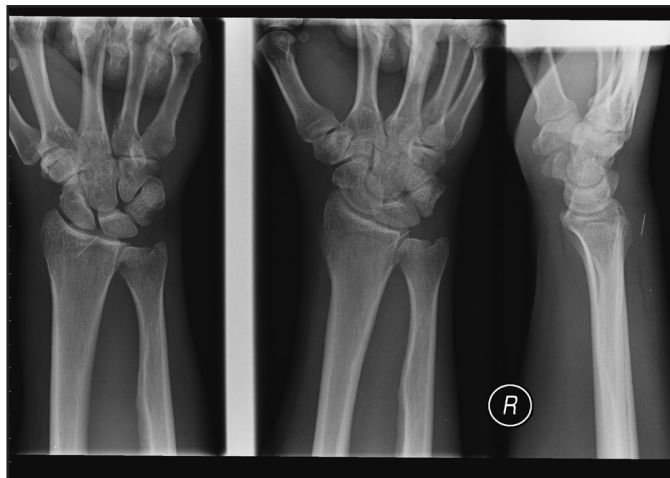
The right dorsal forearm from one centimeter proximal to right antecubital crease was erythematous, edematous, and tender. There was warmth but no areas of drainage or fluctuance. Range of motion was normal at the elbow and wrist. No open wound was evident. The remainder of the examination was negative.

Laboratory data were unremarkable.

Wrist radiographs revealed a linear, needlelike, opaque foreign body in the soft tissues at the dorsal aspect, distal radius (Figure 1).

## Treatment

The patient was hospitalized, treated with intravenous vancomycin, and the needle was surgically extracted using ultrasound guidance.

**Figure 1:** Soft Tissue and Skin Infections in IVDA.

## Outcome

The patient did well. Treatment was successful because of appropriate antibiotics, extraction of the foreign body, and adequate tissue penetration of the vancomycin. He was discharged on hospital day nine.

## Discussion

Intravenous drug users commonly develop skin and soft tissue infections ranging from mild to life threatening. Complications from infection result in 60-80% of total hospital admissions for this group. If not adequately treated, cellulitis may progress to pyogenic myositis, necrotizing fasciitis, osteomyelitis, septic arthritis, abscesses, bacterial endocarditis, and sepsis. Severe infections can result in high fatality rates and may not earlier be detected clinically. Imaging is an important diagnostic tool to differentiate between superficial and deep-seated involvement of the infection.<sup>1,2</sup> Imaging leads to aggressive and necessary surgical intervention in cases of deep infection, such as abscesses, necrotizing fasciitis, or pyomyositis.<sup>1,2</sup>

IVDA patients present with varied complication. Foreign bodies, such as embedded needles, may complicate the presentation.<sup>2</sup> Sub-optimal nutritional status and poor compliance with medication often lead to serious and deeper infections in patients with intravenous drug abuse.<sup>2</sup>

Soft tissue infections in this group are caused by inoculation of pathogens from the skin, most commonly *Staphylococcus aureus* or *Streptococcus pyogenes*. Delayed presentation results in spread of infection to subcutaneous tissue, muscle, fascia, tendons, as well as adjacent bones and joints. There also may be vascular complications, such as hematomas, aneurysms, septic thrombophlebitis, and arterial emboli. Other sequelae include lymphatic obstruction and emboli leading to endocarditis.<sup>1</sup>

Imaging is helpful in determining extent and location of infection and is also useful in detecting foreign bodies, such as embedded needles.<sup>1</sup>

Ultrasound guidance is excellent for removal of foreign bodies and prevents damage to tissue from attempted blind extraction.<sup>3</sup> Ultrasounds may also detect fluid collections in the soft tissues and muscle.<sup>1</sup> In addition, the sonogram is an effective tool to guide aspiration of intramuscular fluid and fluid collections in infected joints.<sup>1</sup>

CT scans are invaluable for determining depth of infection<sup>4</sup> but detect change in soft tissue density, thus demonstrating the extent of infection. Gadolinium-enhanced MRI also demonstrates inflammatory changes in soft tissues. CT with contrast and MRI imaging are both helpful in detecting abscesses and fasciitis, as opposed to cellulitis.<sup>1</sup> In patients suspected of osteomyelitis, CT detects subtle osteolysis of the cortex or sequestra. MR imaging is also key in making this diagnosis. Both of these imaging techniques pick up joint effusions indicative of septic arthritis, leading to joint aspiration with definitive identification of the causative infective agent.

Missed foreign bodies that remain undetected are problematic in substance abuse patients. Delayed migration of foreign bodies may occur and lead to morbidity. Needle fragments from peripheral veins can lead to pulmonary embolization. Blind attempts at extraction are unwarranted. This often causes tissue damage as well as unsuccessful removal. Imaging should be used liberally for localization if presence of foreign body is suspected.<sup>5,6</sup>

In this IVDA patient population, which may be HIV positive, skin and soft tissue infections are frequently caused by MRSA. Intravenous vancomycin or oral linezolid treat MRSA effectively provided there is adequate dosing and tissue penetration. Osteomyelitis, however, may involve other bacteria: likely, salmonella, mycobacteria, pseudomonas, nocardia, and klebsiella.<sup>1</sup>

## Learning Points

- Skin and soft tissue infection is common in IV drug abusers. It must be treated aggressively to prevent serious complications.
- MRSA infections are effectively treated with IV vancomycin or oral linezolid as long as there is adequate dosing and tissue penetration.
- Blind attempts at foreign body extraction without accurate localization may result in tissue, neural, and vascular damage.
- Imaging tools are invaluable in determining depth and extent of skin and soft tissue infection.
- Ultrasound, CT scan, and MRI are excellent tools for foreign body localization.

*Nancy Lutwak, MD, is Attending Physician and Clinical Assistant Professor, Department of Emergency Medicine, VA New York Harbor Healthcare System, New York City.*

*Potential Financial Conflicts of Interest: By AJCM® policy, all authors are required to disclose any and all commercial, financial, and other relationships in any way related to the subject of this article that might create any potential conflict of interest. The author has stated that no such relationships exist.*

## References

1. Theodorou SJ, Theodorou DJ, Resnick D. Imaging Findings of complications affecting the upper extremity in intravenous drug users: featured cases. *Emerg Radiol.* 2008;15:227-239.
2. Warner RM, Srinivasan JR. Protean manifestations of intravenous drug use. *Surg J R Coll Surg Edinb Irel.* 2004;3:137-140.
3. Callegari L, Leonardi A, Bini A, Sabato C, et al. Ultrasound-guided removal of foreign bodies: personal experience. *Eur Radiol.* 2009;19:1273-1279.
4. Fayad LM, Carrino JA, Fishman EK. Musculoskeletal Infection: Role of CT in the Emergency Department. *Radiographics.* 2007;27(6):1723-36.
5. Ozsarac M, Demircan A, Sener S. Glass Foreign Body in Soft Tissue: Possibility of High Morbidity Due To Delayed Migration. *The J of Emerg Med.* 2011;41(6):e125-e128.
6. Brunette DD, Plummer DW. Pulmonary Embolization of Needle Fragments Resulting from Intravenous Drug Abuse. *Am J Emerg Med.* 1988;6:124-127.
7. Weigelt J, Itani K, Stevens D, Lau W, et al. Linezolid versus Vancomycin in Treatment of Complicated Skin and Soft Tissue Infections. *Antimicrob Agents Chemother.* 2005;49(6):2260-2266.
8. Stein GE, Wells EM. The importance of tissue penetration in achieving successful antimicrobial treatment of nosocomial pneumonia and complicated skin and soft-tissue infections caused by methicillin-resistant *Staphylococcus aureus*: vancomycin and linezolid. *Curr Med Research and Opinion.* 26(3):571-588(18).