



CASE REPORT

Fetal Heart Rate Misrepresented by Maternal Heart Rate: A Case of Signal Ambiguity

Ikechukwu Emereuwaonu, MD

Abstract

Interpretation of Electronic Fetal Heart Rate (EFHR) patterns, as the major component of the non stress test (NST) and contraction stress test (CST), is a required skill for prenatal and delivery care. However, there are situations where the fetal heart rate tracing may be misleading.¹

Because the decision to perform emergency cesarean section frequently hinges on (EFHR) monitoring, it is important to recognize situations where EFHR monitoring could be misleading.

This report describes a case in which the maternal heart rate was detected by the EFHR monitor and mistaken for a reas-

suring (category I)⁶ fetal heart rate tracing during second stage of labor. The mistake was discovered immediately postpartum when the “reassuring fetal strip” continued on the monitor even though the neonate had delivered, indicating that the tracing was actually of maternal origin. This highlights the concept of signal ambiguity.¹

Signal ambiguity is a situation in which the EFHR mistakenly detects and displays the maternal pulse on the fetal heart rate monitor. This case report shows how this can occur, when it should be suspected, and suggests methods for evaluation, confirmation, and correction. This helps physicians to intervene appropriately or avoid significant interventions based on misleading readings.

Figure 1A: The FHR began to decrease from 120s to 90s.

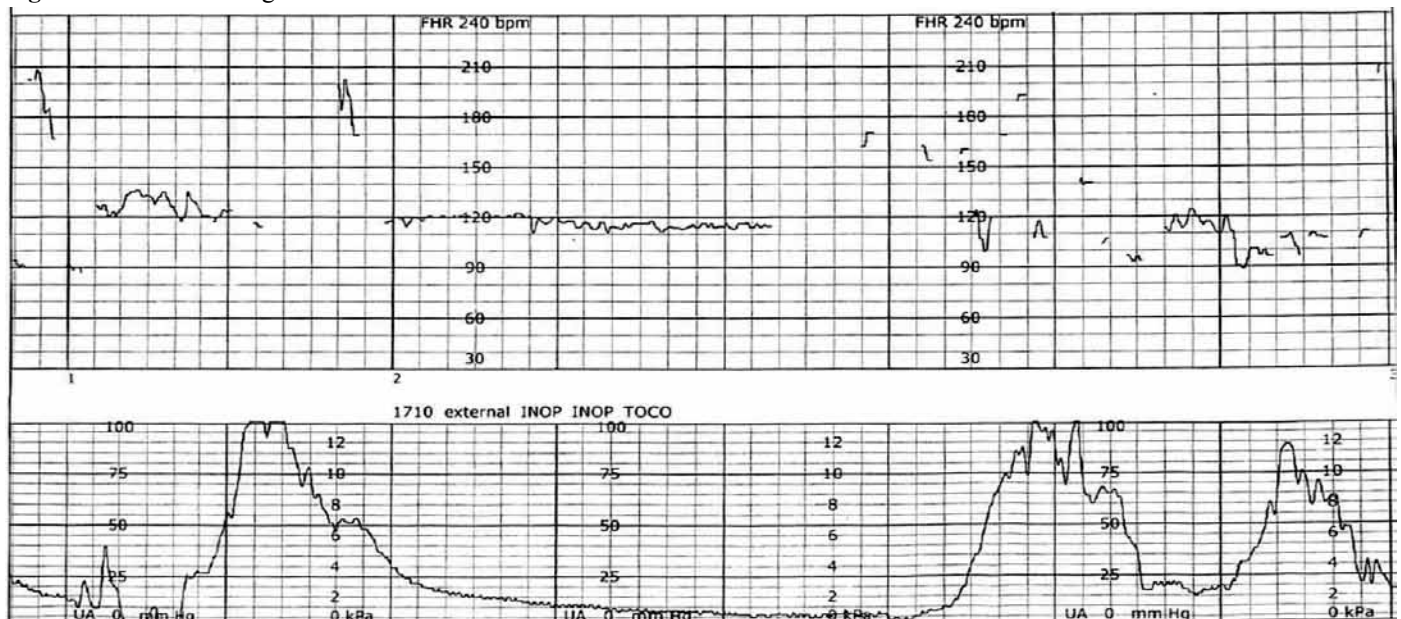


Figure 1B: The FHR began to decrease from 120s to 90s.

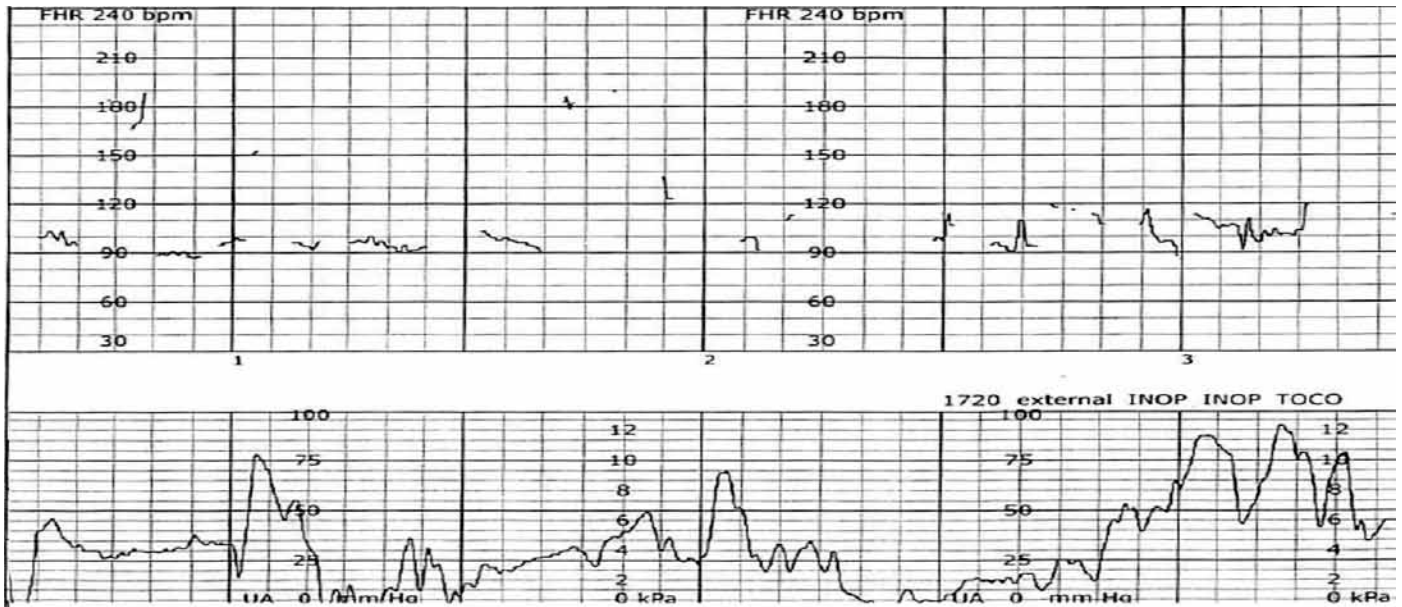
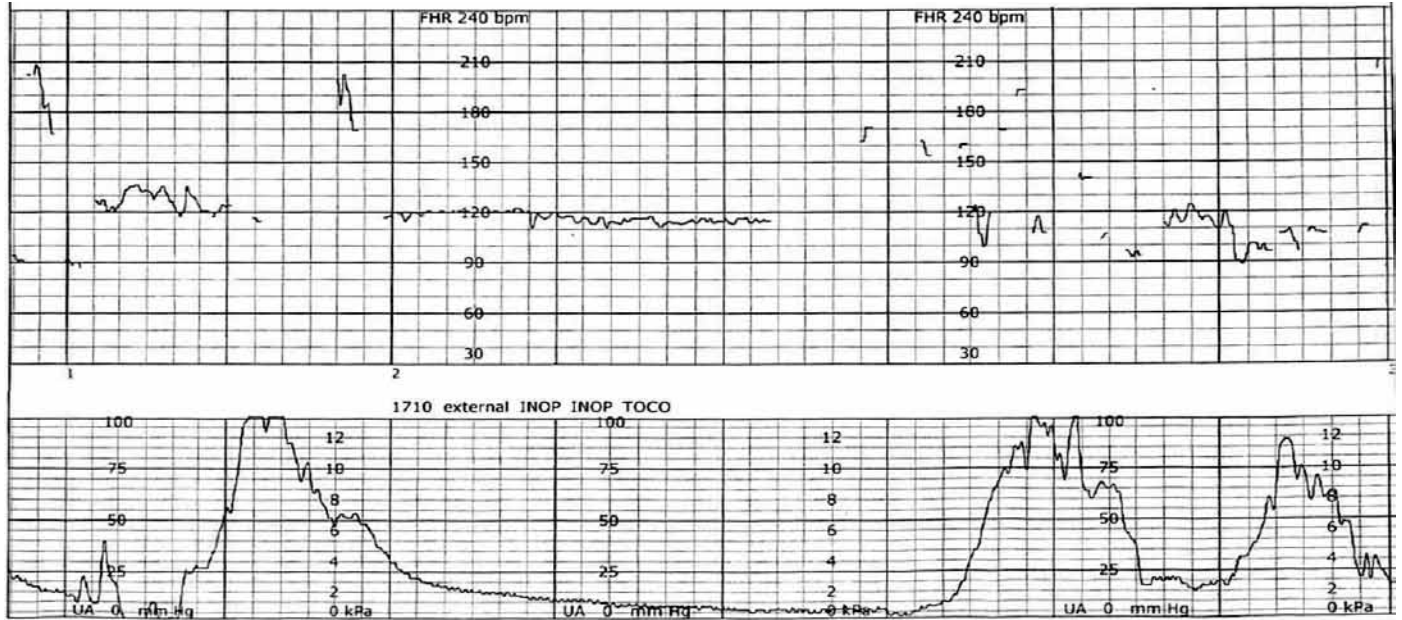


Figure 2A: Maternal pulse tracing as fetal heart rate.



Case report – Signal Ambiguity

A 19-year old Gravida 1 Para 0 had her initial prenatal visit in the first trimester. There were 17 prenatal visits. Her estimated due date (EDD) was established by first trimester ultrasound. Prenatally there were no complications. She presented at 39 weeks and 4 days with ruptured membranes and proceeded to active labor. Initially the cervix was 3cm dilated and 90% effaced. The fetal head was at -2 cm station, and the presentation was vertex. She was contracting every four minutes in a regular and painful pattern. She was admitted to the hospital in anticipation of delivery.

During electronic fetal monitoring (EFM) fetal heart rate (FHR) ranged from 110 to 130s with an isolated peak to 150s.

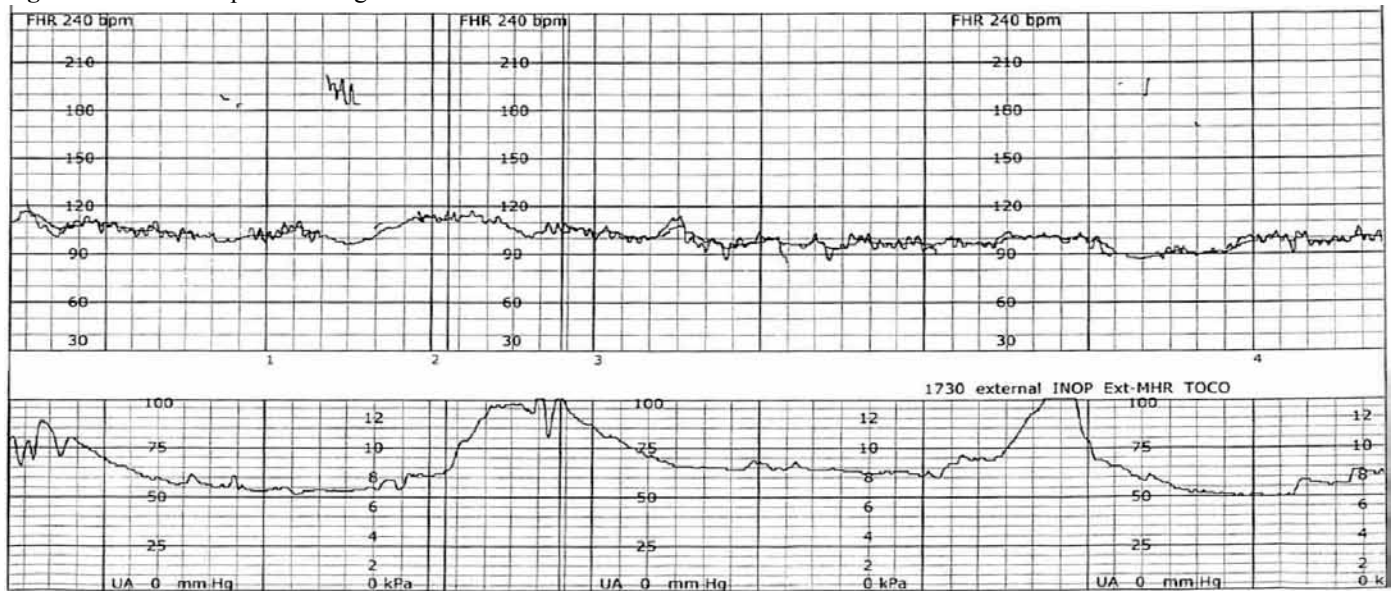
At about seven hours after admission, patient was sat up for epidural placement, and the nurse noted that the FHR appeared to decelerate to the 90-100s and stayed down for seven minutes.

During this time the nurse anesthetist was able to access the epidural space. Once the epidural catheter was in, the patient was turned on her side.

An attempt to stimulate the fetal scalp and place an fetal scalp electrode (FSE) failed. Backup for a possible cesarean section was notified.

The maternal pulse (read by the pulse oximeter) approximated the FHR by one to two beats. A review of the FHR tracing found subtle accelerations with each contraction. The maternal pulse tracing on the cardiograph was started. As noted in

Figure 2B: Maternal pulse tracing as fetal heart rate.

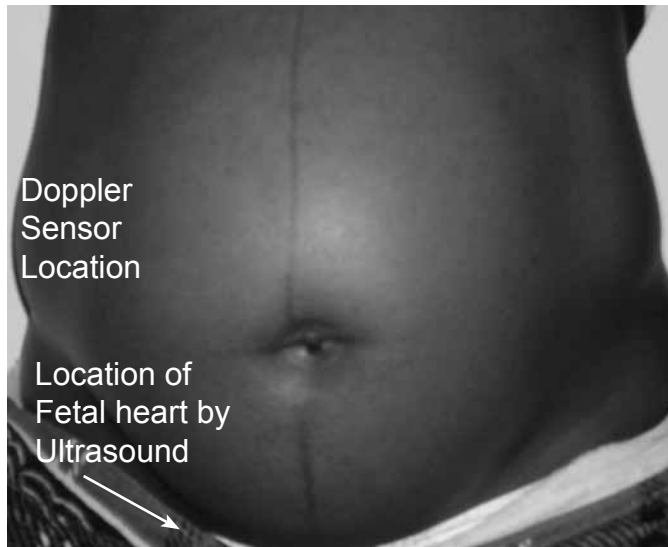


the Figure 2A, the maternal pulse traced together with the fetal heart rate.

To determine the location of the FHR, a bedside ultrasound was used to locate the fetal heart (see Diagram I). The fetal heart was located just above the pubis and right of midline. The Doppler sensor had been placed further superior.

We repositioned the sensor and the FHR tracing was at 120s and the MHR tracing at 80-90s.

Diagram I: Fetal heart location by Ultrasound.



The labor continued uneventful and MHR tracing was turned off. Eventually, the patient became 10cm dilated and started pushing as seen in figure 5A- C.

After an hour-long second stage of labor, a live infant male was born with Apgars 9/9. However, as is demonstrated in Figure 6, the EFHRM monitor continued to detect a fetal heart tracing in the postpartum period, raising the suspicion of signal ambiguity.

Discussion

Despite years of controversy, electronic fetal heart rate monitoring (EFHRM) is the standard of care for evaluation of fetal status during pregnancy and labor.^{4,5} It is the sine qua non of prenatal risk management non stress testing (NST), biophysical profile (BPP), and contraction stress testing (CST). EFHRM is relied upon heavily to make the decision for emergent delivery by cesarean section. However, this technology is not 100% reliable for reasons such as signal ambiguity, as exemplified by the aforementioned case.

Signal ambiguity describes the phenomenon whereby the EFHRM mistakenly detects the maternal heart rate instead of the fetal heart rate. This error may arise from faulty Doppler placement or inability of the cardiotocograph to differentiate FHR from MHR, or both. This phenomenon is not widely known and has been responsible for poor fetal outcomes in the face of seemingly excellent category I tracings.¹

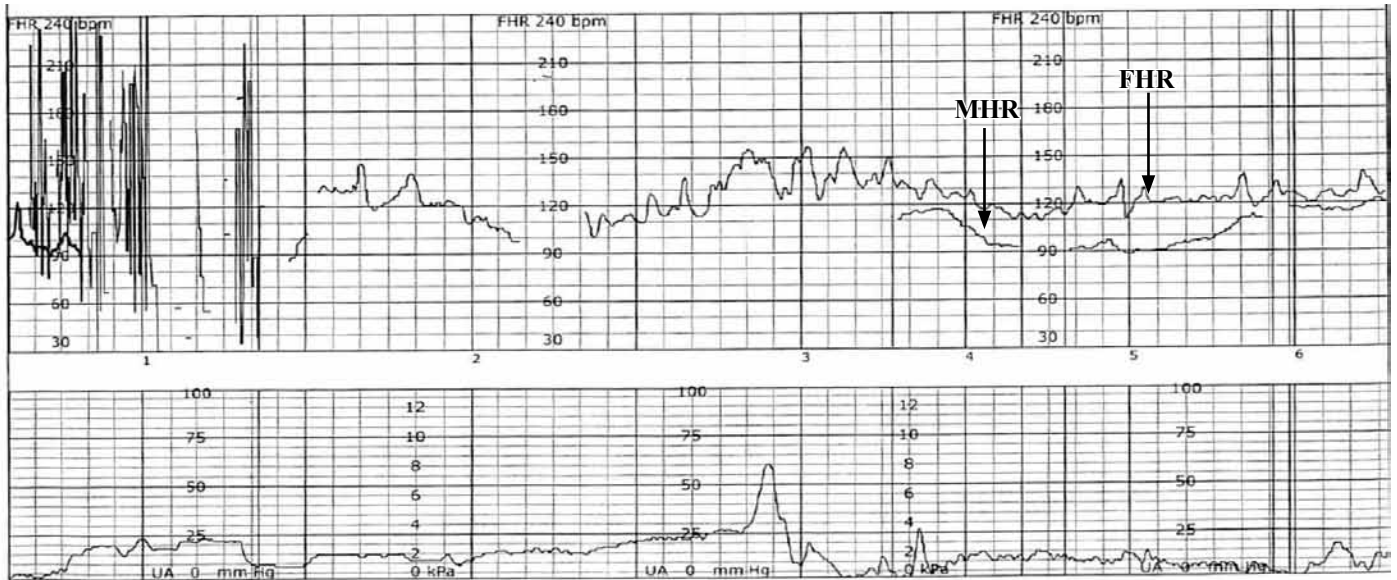
Using the above case as an example, this discussion presents a way to suspect, evaluate, diagnose, and correct any case of signal ambiguity (in singleton pregnancies). This is very important as interventions in labor management are affected by EFHRM. In the above case a cesarean section would have been initiated for non reassuring fetal heart rate tracing (NRFHR) – fetal bradycardia^{4,5,6} had we not recognized that this was a case of signal ambiguity.

When to suspect signal ambiguity

The key to recognizing signal ambiguity is to suspect it when the:

1. FHR is running in the low normal range;³
2. FHR accelerations^{4,5} (sometimes slight with absence of decelerations) are noted with >50% of contraction (especially when pushing);³

Figure 4A: Fetal heart rate and maternal pulse tracing seen differently.



We repositioned the sensor and the FHR tracing was at 120s and the MHR tracing at 80-90s.

Figure 4B: Fetal heart rate and maternal pulse rate tracing as separate entities.

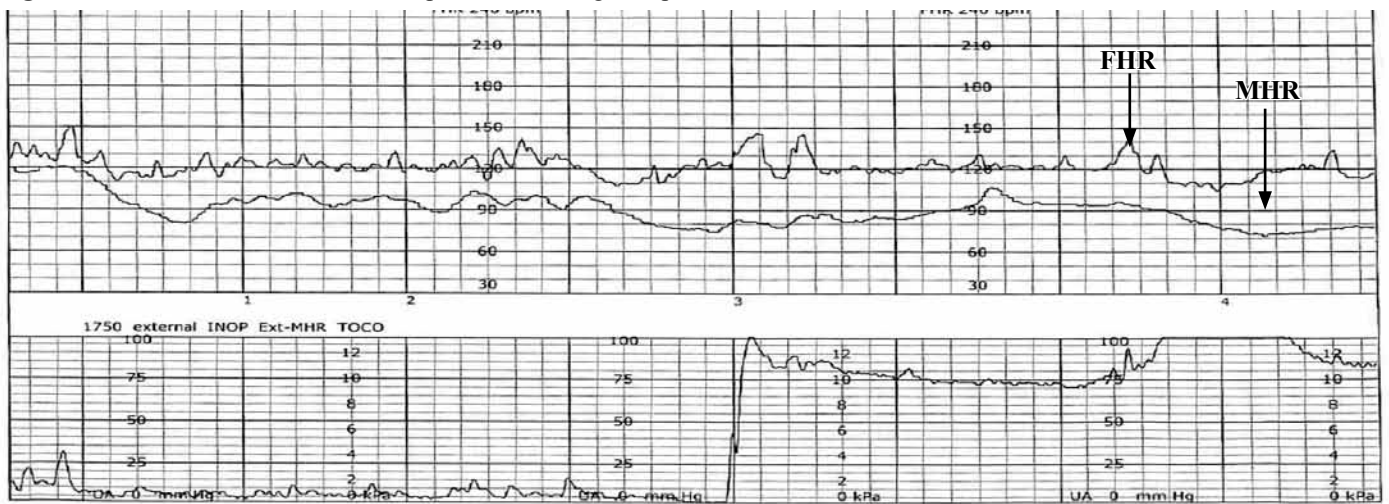


Figure 4C: Fetal heart rate and maternal pulse rate tracing as separate entities.

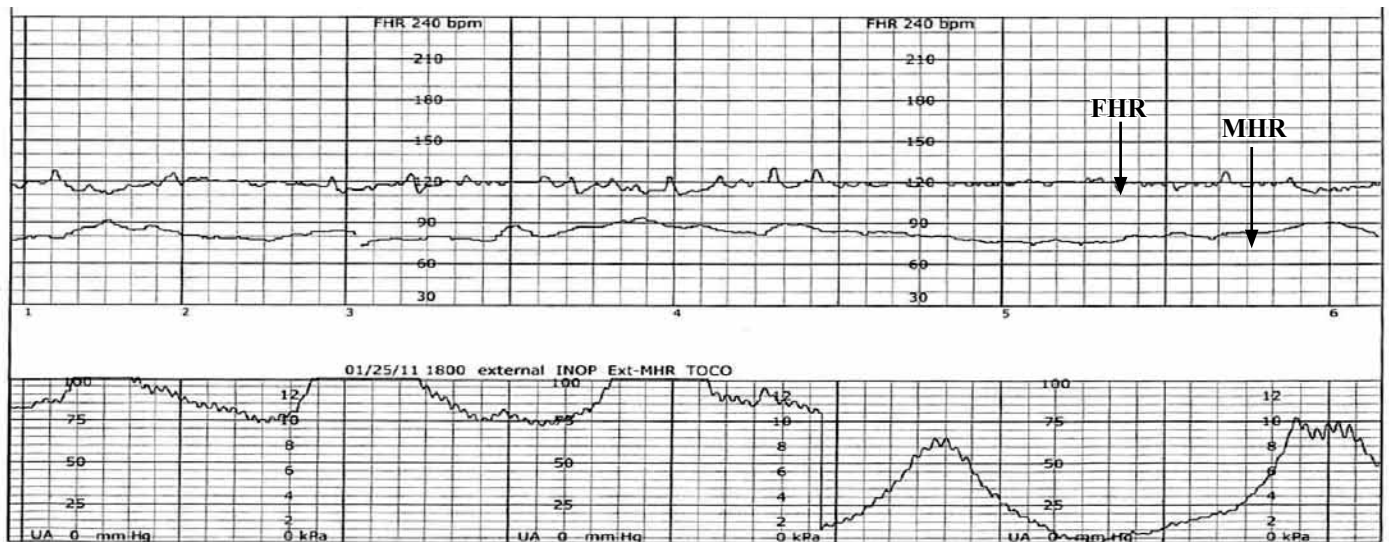
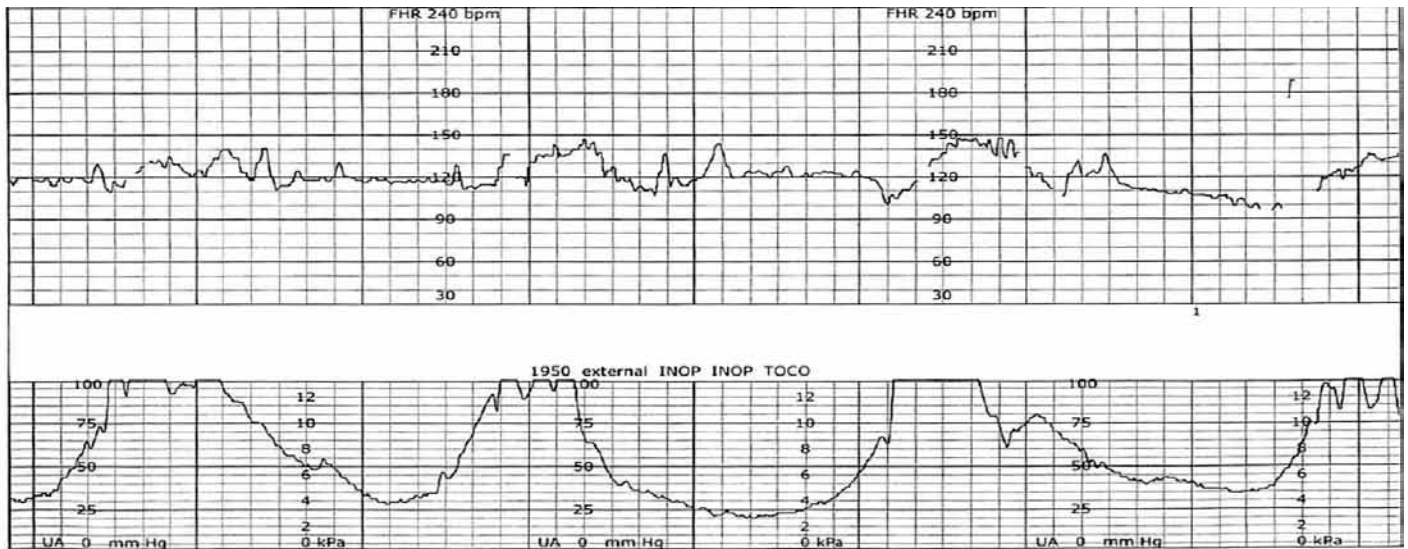
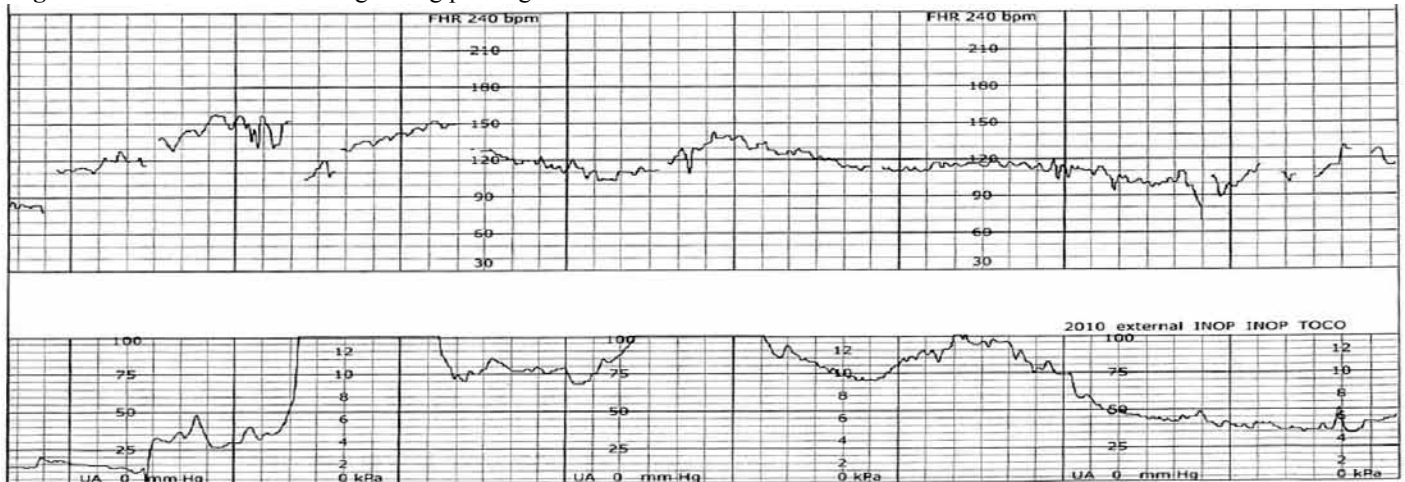
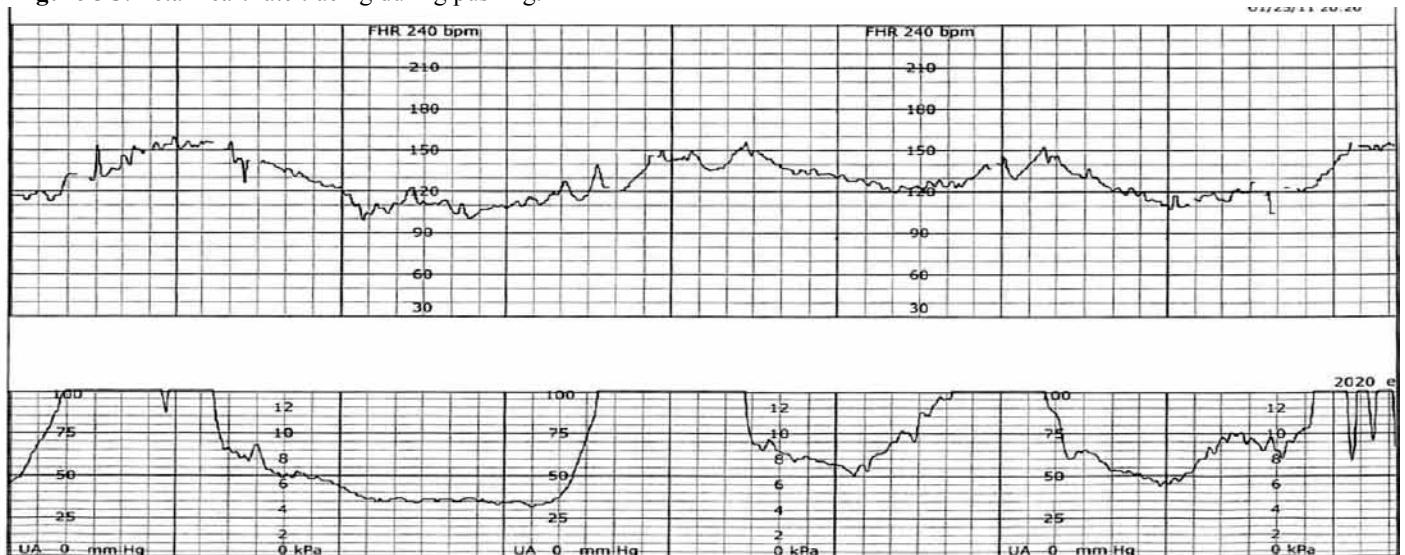
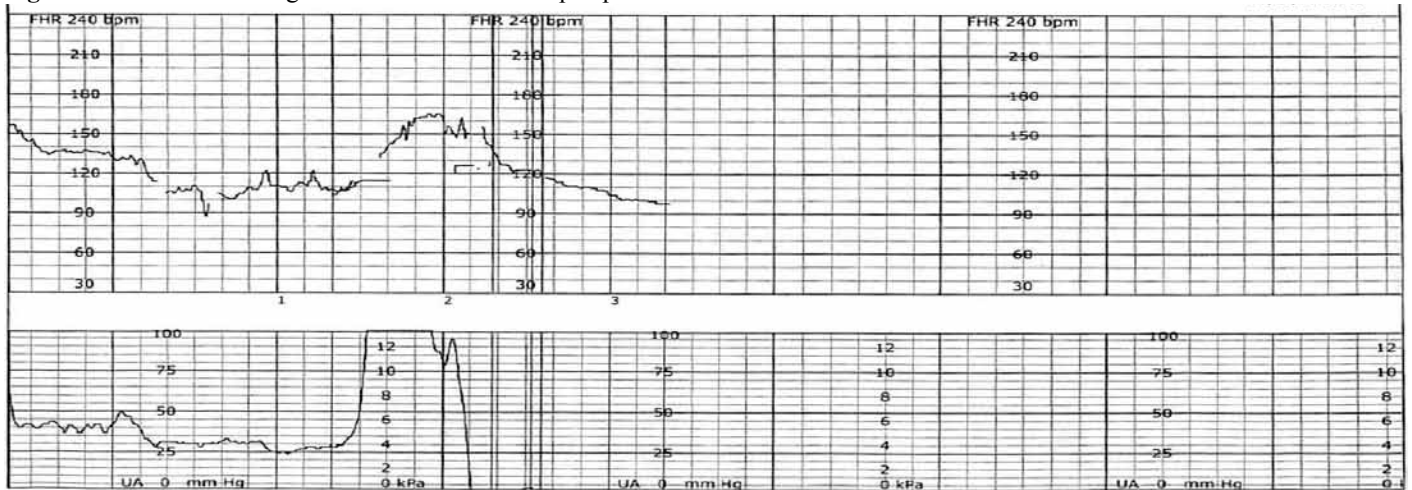


Figure 5A: Fetal heart rate tracing during pushing.

The labor continued uneventful and MHR tracing was turned off. Eventually, the patient became 10cm dilated and started pushing as seen in figure 5A- C.

Figure 5B: Fetal heart rate tracing during pushing.**Figure 5C:** Fetal heart rate tracing during pushing.

After an hour-long second stage of labor, a live infant male was born with Apgars 9/9. However, as is demonstrated in Figure 6, the EFHR monitor continued to detect a fetal heart tracing in the postpartum period, raising the suspicion of signal ambiguity.

Figure 6: Fetal heart tracing continues three minutes postpartum.

3. Apparent FHR deceleration to MHR (or maternal tachycardia into FHR) range that does not recover.³

There **MAY** be a signal break between the switch from fetal to maternal heart rate,¹ as visualized by a distinct discontinuity in the heart tracing. Refer to Figures 1A1B/5A5B/5C/6.

How to evaluate a suspected case of signal ambiguity

Once suspected, signal ambiguity can be evaluated by assessing maternal pulse and comparing it with FHR. Assess pulse by:

1. Counting maternal radial pulse for one minute;
2. Using a pulse oximeter to record a maternal nailbed pulse;
3. Start a MHR pulse oximeter tracing on cardiocotograph and watch rate and pattern (**recommended option**).

If the external FHR and maternal pulse are the same, or closely approximate each other by one to four beats per minute, then signal ambiguity is likely present. Some hospitals already place a pulse oximeter on laboring patients as part of the protocol for epidural anesthesia. Refer to Figures 2A2B .

How to correct a confirmed case of signal ambiguity

Find the fetal heart rate by:

1. Using a **bedside Ultrasound Sound** to locate fetal heart (**recommended option because intrauterine fetal death (IUFD) is a possibility**);
2. Relocate the Doppler sensor until another heart rate (i.e., the FHR) is located that is at least five to ten beats different from MHR;
3. Alternatively, place a fetal scalp electrode (FSE) if possible.

Restart FHR and MHR tracings and watch rate and patterns. The difference should be at least five to ten beats. The MHR

tracing may have subtle acceleration with each (or almost each) contraction or pushing effort. However, the FHR would accelerate randomly or perhaps even decelerate with contraction.³ Refer to Figure 4A14B/4C.

Acknowledgement

I wish to acknowledge Omoniyi Y. Adebisi, MD, CCFP, DABFP, DABPSFO, Surgical Family Medicine Obstetrics for his editing assistance in the preparation of this manuscript.

Ikechukwu Emereuwaonu, MD, is Assistant Program Director, St. Joseph Family Medicine Residency, St. Joseph Hospital Medical Center, Phoenix.

Potential Financial Conflicts of Interest: By AJCM® policy, all authors are required to disclose any and all commercial, financial, and other relationships in any way related to the subject of this article that might create any potential conflict of interest. The author has stated that no such relationships exist.

References

1. Neilson DR, Freeman RK, Mangan S. Signal Ambiguity resulting in unexpected outcome with external fetal heart rate monitoring. *American Journal of Obstetrics & Gynecology*. 2008 June;198(6):717-24. Presented at Vanderbilt High risk OB conference.
2. Nageotte MP. Avoiding 5 common mistakes in fetal heart rate monitoring. *Contemporary Obstetrics and Gynecology*. 2007;52:50-5.
3. Sherman DJ, Frenkel E, Kurzweil Y, Padua A, Arieli S, Bahar M. Characteristics of maternal heart rate patterns during labor and delivery. *Obstetrics and Gynecology*. 2002;99:542-7.
4. Rodney JRM, Huntley BJF, Rodney WM. Electronic fetal monitoring Update 2012. *Family Medicine Obstetrics Clin. N. America*. 2012. In Press.
5. American Academy of Family Physicians (AAFP). *Advanced Life Support Obstetrics (ALSO)*. Chapter – Intrapartum Fetal Surveillance. Kansas City, Mo. 2008.
6. Macones GA, Hankins GD, Spongy CY, Hauth J, Moore T. NICHD updates guidelines and 3 tier system. *Obstetrics and Gynecology*. 2008 Sept;112(3):661-6.