



# CORE COMPETENCIES — CHEST X-RAY

## Food Handler with Cough

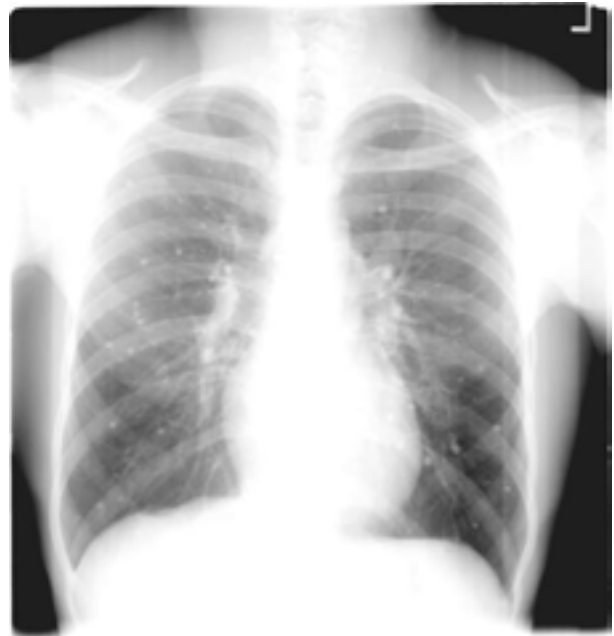Manoj Mazumder, MD

A 21-year-old African-American food handler from Memphis, who works in a nursing home facility, has experienced increasingly severe nausea and vomiting over the past six days. During the last day he has complained of chest pain, slight non-productive cough, and a fever. He denies a previous history of allergy, surgery, or hospitalization. He smoked for two years but quit several years ago. He denies TB exposure, hemoptysis, headache, night sweats, and weight loss. He denies cave exploration and exotic pets.

His vital signs are unremarkable: blood pressure 105/73, pulse 64 beats per minute, oral temperature 99.0° Fahrenheit, respiratory rate 16 per minute and unlabored.

His physical examination is unremarkable. The lungs are clear to auscultation and percussion. Pulse oximeter documents SaO<sub>2</sub> of 99%. The peak flow is 450 L/minute. An electrocardiogram is normal, and the hemogram is normal with a white blood cell count of 4.0 x10<sup>9</sup>/L, and the hemoglobin is 15.1 gms/dl.

The following chest radiogram is obtained, and clinical questions follow. First, there is a postero-anterior view and then a lateral image.



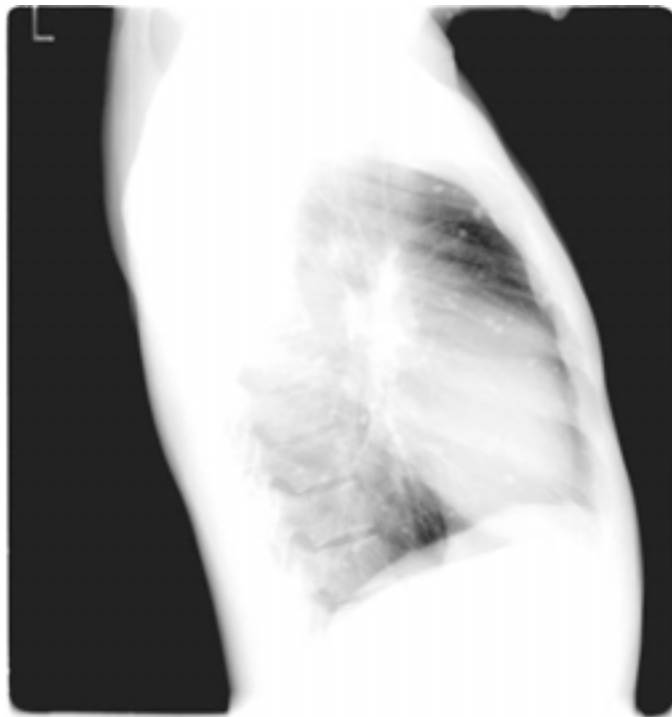
1. The best interpretation of this image is:

- Acute pneumonia
- Secondary tuberculosis
- Primary tuberculosis
- Diffuse bilateral abnormalities of unknown etiology

2. The best management plan would include:

- Hospitalization
- Immediate referral to the public health department
- A PPD skin test with reading in 48-72 hours
- Bronchoscopy following AIDs precautions

The patient returns from the hospital where his HIV and bronchoscopy examinations were “normal.” A PPD was placed, and two days later the induration was noted to be 9 mm. A lateral image from the first day is reviewed.



3. The lateral image is most consistent with:
  - a. Acute pneumonia
  - b. Secondary tuberculosis
  - c. Primary tuberculosis
  - d. Diffuse bilateral abnormalities of unknown etiology
4. This radiograph, present illness, and physical examination are most consistent with:
  - a. Blastomycosis
  - b. Tuberculosis
  - c. Histoplasmosis
  - d. Pneumocystis Carinii
5. Management of this case should include:
  - a. Immediate termination as a food handler
  - b. Quarantine with public health department
  - c. Course of medication as outpatient
  - d. Routine care with observation for changes

## Discussion

In the radiograph both lung fields have multiple scattered small nodules. These were uniformly small, less than 2 mm each. Although there are several differential diagnoses for this pattern, this most likely represents a fungal infection known as histoplasmosis. Tuberculosis and HIV should be excluded, and they were. Inpatient workup was not necessary.

Histoplasmosis is a disease caused by the fungus *Histoplasma capsulatum*. *H. capsulatum* grows in soil and material contami-

nated with bat or bird droppings, including poultry. Spores become airborne when contaminated soil is disturbed. Breathing the spores causes infection. The disease is not transmitted from an infected person to someone else.<sup>1</sup> *Histoplasma capsulatum* may infect anyone. Positive histoplasmin skin tests occur in as many as 80% of the people living in areas where *H. capsulatum* is common, such as the midwestern United States, in the Ohio and Mississippi valleys. Among the endemic mycoses it is the most common cause for hospitalization.<sup>2</sup> Its symptoms vary greatly, but the disease primarily affects the lungs. Most individuals with histoplasmosis are asymptomatic.

Since person-to-person transmission of histoplasma is not known, the patient can continue working as a food handler. Transmission by organ transplantation has been reported, however.<sup>3,4</sup>

Distinct patterns may be seen on a chest x-ray. Histoplasmoses are healed pulmonary lesions that appear as residual nodules on chest radiography. These are seen here, but his disease has not reactivated. This military pattern of histoplasmosis is frequently accompanied by calcified hilar adenopathy, but that is not seen here. Chronic histoplasmosis can resemble tuberculosis and can worsen over months or years.

Those who develop clinical manifestations are usually immunocompromised or are exposed to a high quantity of inoculum. Infants, young children, and older persons, in particular those with chronic lung disease, are at increased risk for severe disease. The acute respiratory disease is characterized by respiratory symptoms, a general ill feeling, fever, chest pains, and a dry or nonproductive cough. The disseminated form is fatal unless treated.

## Treatment for Pulmonary Histoplasmosis

Clinical practice guidelines for the management of patients with histoplasmosis were updated in 2007 by the Infectious Disease Society of America.<sup>5</sup>

The therapeutic approach to pulmonary Histoplasmosis varies according to the specific disease process, namely:

1. Acute pulmonary Histoplasmosis
2. Chronic pulmonary Histoplasmosis
3. Mediastinal granulomas
4. Fibrosing mediastinitis
5. Broncholithiasis
6. Pulmonary nodules

This patient has asymptomatic pulmonary nodules. Sites of healed *Histoplasma capsulatum* lung infection can evolve into pulmonary nodules that can persist long term.<sup>5,6</sup> They are typically asymptomatic and are identified incidentally on chest x rays or CT imaging. In the setting of isolated nodules, there is no evidence that antifungal therapy is beneficial.<sup>5,7</sup> Antifungal medications are used to treat severe cases of acute histoplasmosis and all cases of chronic and disseminated disease. Mild

disease usually resolves without treatment. Past infection results in partial protection against ill effects if reinfected.<sup>5</sup> *Histoplasma* species may remain latent in healed granulomas and recur due to subsequent cell-mediated immunity impairment.

## Diagnosis

Culture of *Histoplasma capsulatum* from bone marrow, blood, sputum, and tissue specimens is the definitive method of diagnosis. Demonstration of the typical intracellular yeast forms by microscopic examination strongly supports the diagnosis of histoplasmosis when clinical, epidemiologic, and other laboratory studies are compatible.

An antigen detection test used on urine and serum is a rapid, commercially available diagnostic test. Antigen detection is most sensitive for severe, acute pulmonary infections and for progressive disseminated infections. It often is transiently positive early in the course of acute, self-limited pulmonary infections. A negative test does not exclude infection.

In this case, these healed pulmonary nodules will require no further investigations. Further, nothing will be gained from antigen tests or skin tests at this time. Surveillance at six to twelve months and as new symptoms arise seems reasonable.

*Manoj Mazumder, Department of Family Medicine, University of Arkansas Medical Sciences, Little Rock.*

*Potential Financial Conflicts of Interest: By AJCM® policy, all authors are required to disclose any and all commercial, financial, and other relationships in any way related to the subject of this article that might create any potential conflict of interest. The author has stated that no such relationships exist.*

## References

1. <http://www.cdc.gov/niosh/hi97146.html> DHHS (NIOSH) Publication No. 97-146 September 1997.
2. Chu JH, Feudtner C, Heydon K, et al. Hospitalizations for endemic mycoses, a population based study. *Clin Infect Dis*. 2006;42:822-825.
3. Limaye AP, Connolly PA, Sager M, et al. Transmission of *Histoplasma Capsulatum* by organ transmission. *New Engl J Med*. 2000;343:1163-1166. <http://nejm.highwire.org/cgi/reprint/343/16/1163.pdf>.
4. Wong SY, Allen DM. Transmission of disseminated histoplasmosis via cadaveric renal transplantation: Case report. *Clin Infect Dis*. 1992;14:232-4.
5. Wheat J, Freifeld AG, Kleiman MB, et al. Clinical practice guidelines for the management of patients with histoplasmosis: 2007 update by the Infectious Diseases Society of America. *Clin Infect Dis*. 2007;45(7):807-25.
6. Goodwin RA Jr, Snell JD Jr. The enlarging *Histoplasma*. Concept of a tumor-like phenomenon encompassing the tuberculoma and coccidioidyoma. *Am Rev Dis*. 1969;100:1.
7. Benson CA, Kaplan JE, Masur H, et al. Treating opportunistic infections among HIV-infected adults and adolescents: Recommendations from CDC, the National Institutes of Health, and the HIV Medicine Association/ Infectious Diseases Society of America. *MMWR Recomm Rep*; 2004; Vol. 53; pp. 1-112; ISSN: 1545-8601; PUBMED: 15841069

Answers 1-a; 2-c; 3-d; 4-c; 5-d